

Whole Range of Respiratory Support in a Pregnant Woman with a Severe Form of COVID-19 Infection: A Case Report

Berić, Sanja; Nesek Adam, Višnja; Šklebar, Ivan; Klancir, Tino; Žižak, Mark; Mličević, Marin

Source / Izvornik: *Acta clinica Croatica*, 2023, 62., 154 - 159

Journal article, Published version

Rad u časopisu, Objavljena verzija rada (izdavačev PDF)

<https://doi.org/10.20471/acc.2023.62.s1.21>

Permanent link / Trajna poveznica: <https://um.nsk.hr/um:nbn:hr:144:328489>

Rights / Prava: [In copyright](#)/[Zaštićeno autorskim pravom](#).

Download date / Datum preuzimanja: **2025-02-22**



Repository / Repozitorij:

[Digital Repository of Bjelovar University of Applied Sciences](#)



WHOLE RANGE OF RESPIRATORY SUPPORT IN A PREGNANT WOMAN WITH A SEVERE FORM OF COVID-19 INFECTION: A CASE REPORT

Sanja Berić^{1,2}, Višnja Neseck Adam^{1,2,3}, Ivan Šklebar^{1,2,4,5}, Tino Klancir¹, Mark Žižak¹
and Marin Mličević¹

¹Department of Anesthesiology, Resuscitation and Intensive Care, Sveti Duh University Hospital, Zagreb, Croatia;

²Faculty of Medicine, Josip Juraj Strossmayer University of Osijek, Osijek, Croatia;

³Libertas International University, Zagreb, Croatia;

⁴Catholic University of Croatia, Zagreb, Croatia;

⁵Bjelovar University of Applied Sciences, Bjelovar, Croatia

SUMMARY – Acute respiratory syndrome caused by a novel coronavirus (SARS-CoV-2) in pregnant women can progress to a critical condition. In this paper, we present a case of a woman in the 28th week of gestation hospitalized due to respiratory insufficiency caused by COVID-19 infection and consequent bilateral pneumonia with development of severe acute respiratory distress syndrome. Noninvasive ventilation through a face mask was started but due to progression of respiratory insufficiency with high FiO₂ and positive end expiratory pressure (PEEP), we decided to intubate the patient, after which obstetricians agreed to complete pregnancy by cesarean section. The clinical course was complicated by desaturation and bradycardia with recurring asystole which recovered after the use of atropine. The patient was increasingly difficult to mechanically ventilate on the PSIMV modality (tidal volume [TV] <200 mL). She was switched to ASV modality (TV up to a maximum of 350 mL, ASV 130%, PEEP 16 cm H₂O, FiO₂ 100%, RR 25/min, pPeak 35 cm H₂O, pPlateau 35 cm H₂O), after which peripheral saturation recovered to 89%. Due to inadequate mechanical ventilation, the patient was transferred to Dr. Fran Mihaljević University Hospital for Infectious Diseases in order to perform extracorporeal membrane oxygenation (ECMO). Owing to all of the measures taken, recovery followed after 13 days on ECMO.

Key words: *COVID-19; Pregnancy; Cesarean section; Spontaneous pneumothorax; ARDS; ECMO*

Introduction

Severe acute respiratory syndrome coronavirus 2 (SARSCoV2) is a novel coronavirus that causes a potentially serious respiratory disease, which has spread all around the world and affected the population across all age groups including pregnant women¹.

Pneumonia is one of the most common non-obstetric infections in pregnancy and coronavirus disease 2019 (COVID-19) infection that also tends to affect the lungs². The incidence of COVID-19 infection in pregnant women is not higher than the incidence in all women of reproductive age³. In pregnancy, total lung capacity, functional residual capacity, and expiratory reserve volume are physiologically reduced^{4,5}. As the gravid uterus grows, there is significant reduction in functional residual capacity and compliance of the respiratory system resulting in an increased work of

Correspondence to: *Mark Žižak, MD*, Department of Anesthesiology, Resuscitation and Intensive Care, Sveti Duh University Hospital, Sveti Duh 64, HR-10000 Zagreb, Croatia
E-mail: m_zizak@hotmail.com

breathing⁶. It has been shown that coronavirus infection in pregnant women can progress to a critical condition and even end lethally. Therefore, such patients are at a higher risk of admission to the intensive care unit (ICU), mechanical ventilation, and extracorporeal membrane oxygenation (ECMO)^{3,7,8}.

Case Report

In this paper, we present a case of a 35-year-old woman at 28th week of gestation, who was transferred from a general hospital to our COVID ICU due to respiratory insufficiency caused by COVID-19 bilateral pneumonia with development of severe acute respiratory distress syndrome (ARDS). She had healthy pregnancy and was estimated as American Society of Anesthesiologists Physical Status 2 (ASA PS2). The symptoms occurred 7 days before arrival to the general hospital in the form of dry cough and fever up to 39 °C. She had not been vaccinated nor had prior SARS-COV-2 infection. COVID-19 was confirmed by polymerase chain reaction (PCR) testing 2 days before arriving to the hospital. She spent 2 days in the general hospital on high-flow nasal oxygen (HFNO) therapy before decision was made to transfer her to our ICU because the hospital she was initially admitted to did not have COVID ICU, therefore appropriate care for the mother and the child in case of further complications was not available. Upon arrival to our hospital, the patient was conscious, tachycardic (pulse 115/min), hypotensive (blood pressure 80/50 mm Hg), tachypneic (RR 25/min), peripheral saturation 85% on 15 L/min of oxygen *via* face mask. She was sweating and feeling anxious, but did not have signs of cyanosis. Without delay, she was put on noninvasive ventilation *via* face mask (positive end expiratory pressure [PEEP] 18 cm H₂O, PS 7 cm H₂O, FiO₂ 80%), with prompt recovery of peripheral saturation and decrease in respiratory frequency. Gynecologic examination was also performed and cardiotocography (CTG) showed no abnormalities. Chest x-ray (Fig. 1) revealed bilateral spotty, predominantly peripheral infiltrates in all lung fields on the right and in the upper and middle pulmonary fields on the left, along with pneumomediastinum and subcutaneous soft tissue emphysema in the thorax and neck. After 2 days in COVID ICU, the patient was still on a noninvasive ventilation (NIV) mask with increasing FiO₂ (up to 70%) and pressure support requirements (PS 10 cm

H₂O) due to successively lower PaO₂/FiO₂ (P/F) ratios (97 mm Hg) in accordance with arterial blood gas analyses (PaO₂:9kPa). A decision to intubate the patient and start mechanical ventilation was made in consultation with obstetricians, who decided to perform cesarean section. Upon intubation, subcutaneous emphysema of the right supraclavicular region was observed, therefore a central venous line was placed in the right subclavian vein. Pleural movement was verified by ultrasound on both sides and chest x-ray was performed, which was read later. Subsequently, emergency transfer to the operating room was organized to perform urgent cesarean section. Transfer was performed with the use of a transportable ventilator, standard monitoring and perfusers (rocuronium, propofol, dexmedetomidine). Transfer was completed in 10 minutes. Upon arrival in the operating room, due to progressive fall of SpO₂ (down to 74%) and the finding of right-sided pneumothorax on x-ray (Fig. 2), attending anesthesiologist immediately performed thoracocentesis in the 3rd intercostal space in the right medioclavicular line, after which plenty of air was released along with partial recovery of peripheral saturation. During the operation, she was mechanically ventilated on a volume control mode (tidal volume [TV] 450 mL, PEEP 15 cm H₂O, FiO₂ 100%, RR 20/min) with oxygen, sevoflurane and above-mentioned medications on perfusion. Upon completion of the cesarean section, general surgeon placed a thoracic drain, which led to complete recovery of peripheral saturation. Follow-up multi-slice computed tomography (MSCT) of the thorax (Fig. 3) confirmed right-sided pneumothorax up to 50 mm wide and pneumomediastinum up to 8 mm wide. Afterwards, the patient was returned to COVID ICU in a stable respiratory and hemodynamic state. However, after a couple of hours, desaturation (SpO₂ 77%) and bradycardia below 40/min were noted along with repetitive asystole on electrocardiography (ECG) monitoring, which recovered after atropine injections. The patient was increasingly difficult to mechanically ventilate on the pressure controlled synchronized intermittent mechanical ventilation (PSIMV) modality (TV <200 mL). She was switched to adaptive support ventilation (ASV; TV up to a maximum of 350 mL, ASV 130%, PEEP 16 cm H₂O, FiO₂ 100%, RR 25/min, pPeak 35 cm H₂O, pPlateau 35 cm H₂O), after which peripheral saturation recovered to 89%. In the ABG analysis, the measured values showed pH 7.194, pCO₂ 11.2 kPa, pO₂ 10.9 kPa, BE 2.2, total bicarbon-

ates 30.8, SaO₂ 0.934, lactate 1. The calculated Horowitz index (P/F ratio) was 82 mm Hg and Murray score was 3.8. Due to inadequate ventilation (hypercapnia, high pPeak pressures, low TV), infectious disease specialist was consulted and recommended transfer to Dr. Fran Mihaljević University Hospital for Infectious Diseases (UHID) in order to perform extracorporeal membrane oxygenation (ECMO), which our hospital did not have. Therapy with vvECMO was carried out for a total of 13 days, and due to protracted mechanical ventilation (16 days on ETT), percutaneous tracheotomy was performed. The course of treatment at the UHID was complicated by nosocomial infections (*Acinetobacter baumannii* and *Staphylococcus aureus* from tracheal aspirate), the need for renal replacement therapy with continuous venovenous hemodiafiltration (CVVHDF) due to hypernatremia and volume overload, as well as a series of epileptic attacks. The patient was transferred back to our hospital 27 days later and admitted to non-COVID ICU since she was no longer infectious. She was fully conscious with nonverbal communication, immovable, spontaneously breathing with oxygen supplementation to the tracheal cannula, hemodynamically stable with flaccid tetraparesis due to critical disease polyneuropathy. During hospital stay, the patient gradually recovered with adequate oxygenation on room air (SpO₂ 94%). Her preterm baby developed well under the supervision of neonatologist and was not infected with COVID-19. With thorough physical therapy, neurological function improved significantly and she was discharged to physical rehabilitation institute 47 days after initial admission.

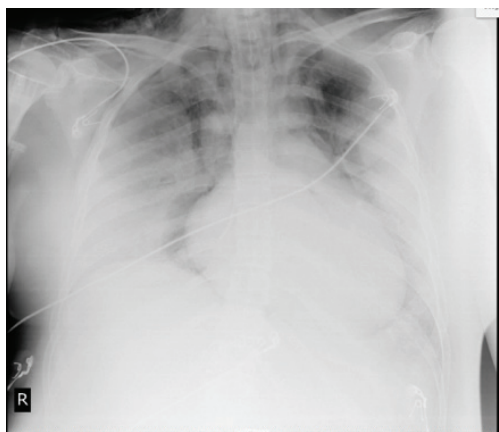

Fig. 1. Chest x-ray before thoracic drain placement.

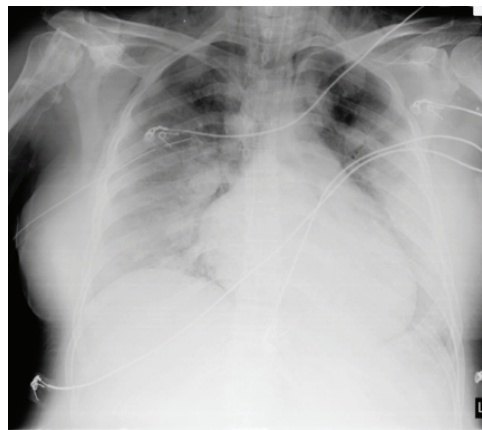


Fig. 2. Chest x-ray after thoracic drain placement.

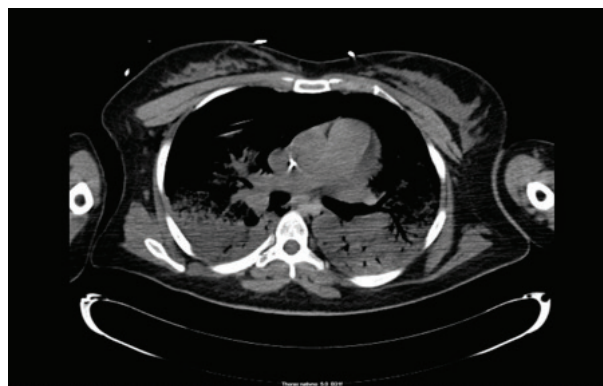

Fig. 3. MSCT of the thorax after thoracic drain placement.

Discussion

Pregnant women infected with severe SARS-CoV-2 may be asymptomatic or symptomatic. Those who are symptomatic appear to be at an increased risk of developing severe COVID-19 sequels compared with nonpregnant reproductive-aged females^{3,9,10}. The rates of miscarriage and congenital anomalies do not appear to be increased in pregnancies affected by COVID-19, and neonatal outcome is generally good⁹. Although the overall rate of congenital infection has been reported to be less than 2% of maternal infections, only a few well-documented cases of probable *in utero* transmission have been published¹¹. Altered immune competence exists in pregnancy in order to allow 'tolerance' of the presence of paternal antigen in fetoplacental tissue. This also results in higher predisposition to the development of infectious diseases and sepsis⁶. Pre-existing comorbidities, non-Caucasian ethnicity,

chronic hypertension, pre-existing diabetes, high maternal age, and high body mass index are risk factors for severe COVID-19 in pregnancy, which our patient did not have^{3,12}. As the fetus is constantly in a state of relative hypoxia, a slight imbalance compromising oxygen supply warrants hastened delivery through performance of emergency lower segment cesarean section⁶. Since our patient was already in a state of hypoxia due to severe ARDS, it was also a decision of our obstetric team to perform emergency cesarean section. Pregnant women with COVID-19 *versus* those without COVID-19 are more likely to have preterm delivery and can be at an increased risk of ICU admission and maternal death. Their babies are more likely to be admitted to the neonatal unit³. COVID-19 infection in pregnant women was associated with higher rates of cesarean section¹³.

According to the COVIDPREG Study Group¹⁴, respiratory management in pregnant women with a severe form of SARS-CoV-2 infection might be similar to that of other patients with COVID-19 and the non- or minimally invasive oxygenation strategies (HFNO and NIV) might be preferred. The use of NIV in hypoxemic respiratory failure (except for pandemic viral illness, studied in SARS and influenza)¹⁵ is not recommended as it carries the risk of delayed intubation, large TVs, and injurious transpulmonary pressures¹⁶. In our case, we also started treatment with NIV since she had already been treated with HFNO before arriving to our hospital. In the most severe patients with persistent or refractory hypoxemia, delivery might be considered to improve maternal respiratory mechanics and oxygenation¹⁴. Cases with severe ARDS should be intubated and receive invasive mechanical ventilation as respiratory failure in ARDS is caused by intrapulmonary ventilation-perfusion mismatch or shunt. Mechanical ventilation with tidal volumes of 4–8 mL/kg and inspiratory plateau pressure less than 30 cm H₂O are recommended¹⁷. It is reported that barotrauma develops at rates of 6.5% during mechanical ventilation (MV) in the treatment of ARDS patients¹⁸. Barotrauma and high positive pressure in the lungs may cause complications such as pneumothorax, pneumomediastinum or subcutaneous emphysema, leading to lengthened duration of ICU admission and increased mortality of patients^{18,19}. In COVID-19 ARDS patients, alveolar injury caused by the infection with the contribution of MV may cause more frequent baro-

trauma compared to classic ARDS and this situation significantly increases the duration of MV and intensive care in patients. In terms of reducing mortality and morbidity in these patients, MV treatment should be carefully maintained within the framework of lung protecting strategies, and complications should be identified and treated early²⁰. According to the ARDS Clinical Practice Guidelines, the ventilation modes of commonly used ventilators are VCV and PCV, but it is unclear which of the ventilation modes is more beneficial for patient prognosis²¹. In our case, we decided to use PSIMV and ASV modes because only on these modes it was possible to reach somewhat adequate TVs. It is reasonable to complete pregnancy if the lung function is significantly impaired because hypoxemia of the mother can significantly endanger the fetus. In COVID-19, refractory hypoxemia is common among the critically ill with ARDS despite invasive mechanical ventilation and is further complicated by respiratory and circulatory failure. This difficult situation calls for the use of ECMO to assist respiration and circulation if necessary, as shown in our case²².

Extracorporeal membrane oxygenation is a form of cardiopulmonary bypass used in patients who are impossible to oxygenate or ventilate with common ventilators. In this procedure, with the help of a special device, venous blood is drained from the body, oxygenated and then returned to the patient. The main goal of ECMO is to fulfill oxygen supply to tissues and to remove carbon dioxide (CO₂) in patients with severe form of lung or heart failure, when they are refractory to conventional treatment methods, as it was in our case. Venovenous (v-v) ECMO is used in patients with potentially reversible ARDS. Indications for ECMO are PaO₂/FiO₂ <80 mm Hg, Murray score 3–4 or higher, PaCO₂ >80 mm Hg or pH <7.2, P(plateau) >30 cm H₂O, oxygenation index >30 and A-a DO₂ >600 mm Hg, all of which were met in our case^{23,24}. Murray score stratifies severity of acute lung injury and is also used with other clinical factors to help select patients for ECMO. It consists of several variables, i.e., consolidation on chest x-ray, PaO₂/FiO₂ ratio, PEEP, compliance, and COVID-19 infection status²⁵. We decided to consult ECMO center due to inadequate ventilation, respiratory acidosis and hypercapnia in ABG analysis. In elderly patients and in cases where mechanical ventilation lasts for more than 7 days, it is considered that even despite the use of ECMO, the

risk of adverse outcomes is higher, whereas our patient was of younger age, mechanically ventilated for less than 24 hours.

Conclusion

Pregnant patients are a population at a high risk of morbidity and mortality associated with SARS-CoV-2 infection. Consequently, greater attention, surveillance and prompt decision making is critical for preventing maternal and neonatal morbidity and mortality. The use of ECMO is recommended when other respiratory support strategies (noninvasive ventilation, invasive ventilation through an endotracheal tube) are insufficient. Therefore, it can be concluded that the multidisciplinary approach in this patient provided optimal care.

References

1. Trapani Júnior A, Vanhoni LR, Silveira SK, Marcolin AC. Childbirth, puerperium and abortion care protocol during the COVID-19 pandemic. *Rev Bras Ginecol Obstet.* 2020;42:349-55. doi: 10.1055/s-0040-1713587.
2. Brito V, Niederman MS. Pneumonia complicating pregnancy. *Clin Chest Med.* 2011;32:121-32. doi: 10.1016/j.ccm.2010.10.004.
3. Allotey J, Stallings E, Bonet M, *et al.* Clinical manifestations, risk factors, and maternal and perinatal outcomes of coronavirus disease 2019 in pregnancy: living systematic review and meta-analysis. *BMJ.* 2020;370:m3320. doi: <https://doi.org/10.1136/bmj.m3320>.
4. Hughes SC, Levinson G, Rosen MA, editors. *Shnider and Levinson's Anesthesia for Obstetrics.* 4th ed. Philadelphia: Lippincott, Williams and Wilkins, 2002.
5. Majerić-Kogler V, Ivančan V, editors. *Postgraduate Training in Anesthesiology – Course 4.* Opatija: November 20-22, 2009. (in Croatian)
6. Chan YK, Chue Wai Yim C. Obstetric and foetal physiology – implications for clinical practice in obstetric analgesia and anaesthesia. *Update Anaesth.* 2019;34:81-4. doi: 10.1029/WFSA-D-18-00020.
7. Qeadan F, Mensah NA, Tingey B, Stanford JB. The risk of clinical complications and death among pregnant women with COVID-19 in the Cerner COVID-19 cohort: a retrospective analysis. *BMC Pregnancy Childbirth* 2021;21:305.
8. Lokken EM, Huebner EM, Taylor GG, Hendrickson S, Vanderhoeven J, Kachikis A, *et al.* Disease severity, pregnancy outcomes, and maternal deaths among pregnant patients with severe acute respiratory syndrome coronavirus 2 infection in Washington State. *Am J Obstet Gynecol.* 2021;225:77.e1-77.e14. doi: 10.1016/j.ajog.2020.12.1221.
9. Berghella V, Highes B. COVID-19: pregnancy issues and antenatal care. UpToDate, Waltham, MA: UpToDate Inc. Available from: <https://www.uptodate.com/contents/covid-19-pregnancy-issues-and-antenatal-care>.
10. Chinn J, Sedighim S, Kirby KA, Hohmann S, Hameed AB, Jolley J, *et al.* Characteristics and outcomes of women with COVID-19 giving birth at US academic centers during the COVID-19 pandemic. *JAMA Netw Open.* 2021;4:e2120456. doi: 10.1001/jamanetworkopen.2021.20456.
11. Allotey J, Chatterjee S, Kew T, Gaetano A, Stallings E, Fernández-García S, *et al.* SARS-CoV-2 positivity in offspring and timing of mother-to-child transmission: living systematic review and meta-analysis. *BMJ.* 2022;376:e067696. doi: 10.1136/bmj-2021-067696.
12. Galang RR, Newton SM, Woodworth KR, Griffin I, Oduyibo T, *et al.* Centers for Disease Control and Prevention COVID-19 Response Pregnancy and Infant Linked Outcomes Team. Risk Factors for Illness Severity Among Pregnant Women With Confirmed Severe Acute Respiratory Syndrome Coronavirus 2 Infection-Surveillance for Emerging Threats to Mothers and Babies Network, 22 State, Local, and Territorial Health Departments, 29 March 2020-5 March 2021. *Clin Infect Dis.* 2021;73(Suppl 1):S17-S23. doi: 10.1093/cid/ciab432.
13. Karimi L, Makvandi S, Vahedian-Azimi A, Sathyapalan T, Sahebkar A. Effect of COVID-19 on mortality of pregnant and postpartum women: a systematic review and meta-analysis. *J Pregnancy.* 2021;2021:8870129. doi: 10.1155/2021/8870129.
14. Péju E, Belicard F, Silva S, Hraiech S, Painvin B, Kamel T, *et al.* Management and outcomes of pregnant women admitted to intensive care unit for severe pneumonia related to SARS-CoV-2 infection: the multicenter and international COVID-PREG study. *Intensive Care Med.* 2022;48:1185-96. doi: 10.1007/s00134-022-06833-8.
15. Rochweg B, Brochard L, Elliott MW, Hess D, Hill NS, Nava S, Navalesi P. Official ERS/ATS clinical practice guidelines: noninvasive ventilation for acute respiratory failure. *Eur Respir J.* 2017;50(2):1602426. doi: 10.1183/13993003.02426-2016.
16. Arabi YM, Arifi AA, Balkhy HH, Najm H, Aldawood AS, Ghabashi A. Clinical course and outcomes of critically ill patients with Middle East respiratory syndrome coronavirus infection. *Annu Intern Med.* 2014;160(6):389-97.
17. Rhodes A, Evans LE, Alhazzani W, Levy MM, Antonelli M, Ferrer R, *et al.* Surviving Sepsis Campaign: International Guidelines for Management of Sepsis and Septic Shock 2016. *Intensive Care Med.* 2017;43:304-77. doi: 10.1007/s00134-017-4683-6.
18. Anzueto A, Frutos-Vivar F, Esteban A, Alía I, Brochard L, Stewart T, *et al.* Incidence, risk factors and outcome of barotrauma in mechanically ventilated patients. *Intensive Care Med.* 2004;30:612-9. doi: 10.1007/s00134-004-2187-7.
19. de Lasseuse A, Timsit JF, Tafflet M, Azoulay E, Jamali S, Vincent F, *et al.*; OUTCOMEREA Study Group. Pneumothorax in the intensive care unit: incidence, risk factors, and outcome. *Anesthesiology.* 2006;104:5-13. doi: 10.1097/00000542-200601000-00003.
20. Guven BB, Erturk T, Kompe Ö, Ersoy A. Serious complications in COVID-19 ARDS cases: pneumothorax, pneumomediastinum, subcutaneous emphysema and haemothorax. *Epidemiol Infect.* 2021;149:e137. doi: 10.1017/S0950268821001291.

21. Tasaka S, Ohshimo S, Takeuchi M, Yasuda H, Ichikado K, Tsushima K, *et al.* J Intensive Care. 2022;10:32. doi: 10.1186/s40560-022-00615-6.
22. Ma X, Liang M, Ding M, Liu W, Ma H, Zhou X, *et al.* Extracorporeal membrane oxygenation (ECMO) in critically ill patients with coronavirus disease 2019 (COVID-19) pneumonia and acute respiratory distress syndrome (ARDS). Med Sci Monit. 2020;26:e925364. doi: 10.12659/MSM.925364.
23. Camboni D, Philip A, Schmid C, Loforte A. Double, triple and quadruple cannulation for veno-arterial extracorporeal membrane oxygenation support: is there a limit? Ann Cardiothorac Surg. 2019;8(1):151-9. doi: 10.21037/acs.2019.01.03.
24. Jayaraman AL, Cormican D, Shah P, Ramakrishna H. Cannulation strategies in adult veno-arterial and veno-venous extracorporeal membrane oxygenation: techniques, limitations, and special considerations. Ann Card Anaesth. 2017;20:11-8. doi: 10.4103/0971-9784.197791.
25. Murray JF, Matthay MA, Luce JM, Flick MR. An expanded definition of the adult respiratory distress syndrome. Am Rev Respir Dis. 1988;138:720-3. doi: 10.1164/ajrccm/138.3.720.

Sažetak

CIJELI RASPON RESPIRACIJSKE POTPORE KOD TRUDNICE S TEŠKIM OBLIKOM INFEKCIJE COVID-19

S. Berić, V. Neseć Adam, I. Šklebar, T. Klancir, M. Žižak i M. Mličević

Akutni respiracijski sindrom uzrokovan novim koronavirusom (SARS-CoV-2) u trudnica se može komplicirati do kritičnog stanja. U ovom radu prikazujemo slučaj trudnice u 28. tjednu trudnoće hospitaliziranu zbog respiracijske insuficijencije uzrokovane infekcijom COVID-19 te posljedičnom obostranom pneumonijom i razvojem teškog ARDS-a. Započeta je neinvazivna ventilacija preko maske za lice, no zbog progresije respiracijske insuficijencije uz visoki FiO_2 i PEEP odlučeno je provesti endotrahealnu intubaciju, nakon čega ginekolozi donose odluku o dovršenju trudnoće carskim rezom. Klinički tijek se komplicira desaturacijom te bradikardijom uz opetovane asistolije koje se oporave nakon primjene atropina. Bolesnicu se sve teže mehanički ventilira na modalitetu PSIMV (TV <200). Stoga je prebačena na modalitet ASV (TV do maksimalno 350 mL, ASV 130%, PEEP 16 cm H_2O , FiO_2 100%, RR 25/min, pPeak 35 cm H_2O , pPlateau 35 cm H_2O), nakon čega se periferna saturacija oporavi do 89%. Žbog neodgovorajuće mehaničke ventilacije bolesnica se premješta u Kliniku za infektivne bolesti "Dr. Fran Mihaljević" zbog indicirane izvantjelesne membranske oksigenacije (ECMO). Zahvaljujući poduzetim mjerama uslijedio je oporavak nakon 13 dana ECMO-a.

Ključne riječi: COVID-19; Trudnoća; Carski rez; Spontani pneumotoraks; ARDS; ECMO